

**XIX. Congress of the
European Association for Cranio-Maxillo-Facial-Surgery**
September 9 to 12, 2008 · Bologna, Italy

Use of Nanoporous Biphasic Grafting Material in Sinus Floor Elevation

Mertens, C.¹ · Kosmehl, H.² · Steveling, H.G.¹

¹Department of Oral and Maxillofacial Surgery · University of Heidelberg · Head of Department: Prof. Dr. Dr. J. Mühling

²Institute of Pathology · HELIOS Clinics Erfurt · Head of Department: Prof. Dr. H. Kosmehl

Objective

In this clinical study the success of a biphasic nanoporous HA/TCP alloplast in human maxillary sinus floor elevations was evaluated. The assessment was based on clinical and radiographic evaluations. Whenever possible, histological and histomorphometrical analyses were conducted.

Material and Methods

56 Sinus floor elevation operations were performed on 40 patients using the method described by Tatum. As grafting material a particular nanoporous HA/TCP alloplast (BONITmatrix®, DOT GmbH, Germany) was used exclusively. The material was mixed with blood taken from the operation site prior to delivery into the sinus cavity. No autologous bone was added.

After 4 months of healing, patients received implants (Astra Tech, Mölndal, Sweden) under local anaesthesia. If possible, vertical bone biopsy specimens were taken for histologic evaluation purposes during this procedure. Ten bone cores were analysed immunohistomorphometrically and immunohistochemically (Osteocalcin, Osteopontin, Tenascin).

Results

After four months of healing, all patients had reached sufficient bone levels for placement of implants. Radiographic evaluations showed a mean bone increase of 9.78 mm (SD: 2.79 mm, min: 4.2 mm, max: 13.2 mm). 78 implants could be inserted with high primary stability. No implant has been lost until now.

The histological analysis of the ten bone cylinders taken, proved good osseointegration of the bone graft material altogether. Immunohistochemical observations showed actively growing bone on resorbing graft material.

The performed histomorphometric analysis revealed that 35.47% was bone, 14.04% remaining grafting material and 50.5% connective tissue and bone marrow.

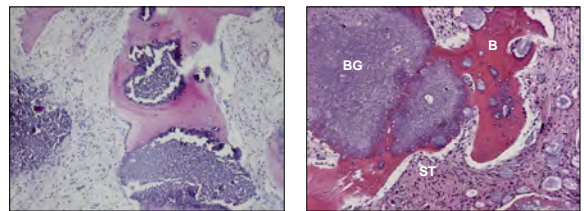


Fig. 1 + 2: B opsy taken from the grafted site after 4 months of healing good osseonegration of the grafted material (HE-staining)
BG - bone graft B - bone ST - soft tissue

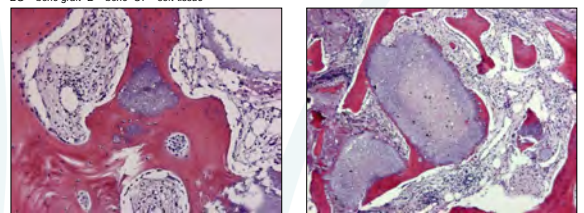


Fig. 2 + 3: the grafted material is completely covered with bone (HE-staining)

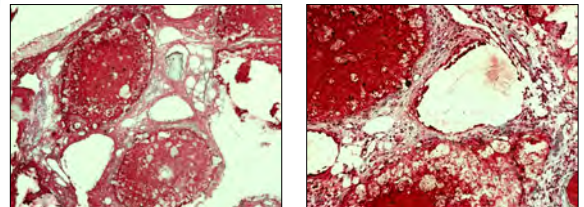


Fig. 5 + 6: Immunohistologic staining shows high bone growth activity surrounding the grafting material
(Fig. 5 Tenascin Fig. 6 Osteocalcin)

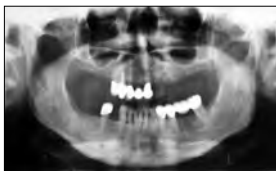

Fig. 7: Case 1 Radiograph preOP

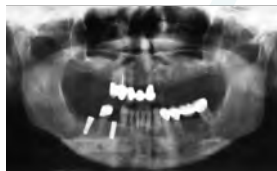

Fig. 8: Case 1 Radiograph 4 months after Sinus floor augmentation

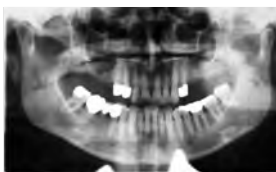

Fig. 9: Case 2 Radiograph preOP

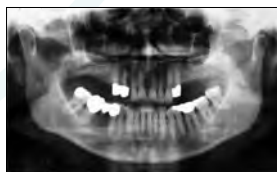

Fig. 10: Case 2 Radiograph postOP

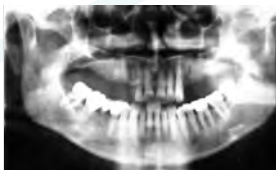

Fig. 11: Case 2 Radiograph 4 months after Sinus floor augmentation

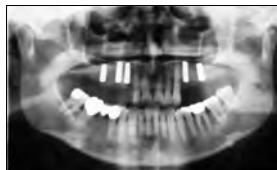


Fig. 12: Case 2 Radiograph after implant insert on

Conclusions

This histological study aimed at evaluating quantity and quality of bone formed after augmentation with a biphasic nanoporous grafting material (BONITmatrix®). Although a radiographic increase of bone height of 9,78 mm after a healing period of 4 months could be achieved and no implant loss was to be reported, clinical and radiographic evaluations cannot prove the exact quantity and structural quality of the bone, as histologic and histomorphometric methods can do.

Histologic examination verified good bone formation on the grafting material. The surface of graft particles was often covered completely with newly formed bone and interconnecting bone could often been seen. The histomorphometric results demonstrate higher bone density and lower remaining grafting material as compared to similar studies (Yildirim et al. 2000) using xenogenic grafts combined with venous blood after 6 months of healing (bone 14.7%, graft residue 29.7%).

Nevertheless, histologically the bone remodeling process is still continuing. Immunohistochemical analyses demonstrate ongoing high activity on the resorbing graft material. Despite of this, the high clinical stability already achieved after a 4 month healing period allowed the insertion of implants already at this stage. Due to the renouncement of the addition of autologous bone, the morbidity of patients was reduced.

CORRESPONDENCE TO:

Mertens, Christian · Department of Oral and Maxillofacial Surgery · University of Heidelberg
INF 400 · 69120 Heidelberg
E-mail christian.mertens@med.uni-heidelberg.de